

Ehlers-Danlos Syndrome Type VIIA and VIIB Result From Splice-Junction Mutations or Genomic Deletions That Involve Exon 6 in the *COL1A1* and *COL1A2* Genes of Type I Collagen

Peter H. Byers,^{1*} Madeleine Duvic,² Mary Atkinson,¹ Meinhard Robinow,³ Lynne T. Smith,¹ Stephen M. Krane,⁴ Marie T. Grealley,⁵ Mark Ludman,⁶ Reuben Matalon,⁷ Susan Pauker,⁸ Deborah Quanbeck,⁹ and Ulrike Schwarze¹

¹Departments of Pathology, Medicine, and Biological Structure, University of Washington, Seattle

²Department of Dermatology, The University of Texas Medical School, Houston

³Department of Pediatrics, The Children's Hospital and Medical Center, Dayton, Ohio

⁴Department of Medicine, Harvard Medical School and Massachusetts General Hospital, Boston

⁵Department of Pediatrics, Eastern Virginia Medical School, Norfolk, Virginia

⁶Department of Pediatrics (Medical Genetics), Dalhousie University, Halifax, Nova Scotia, Canada

⁷Miami Children's Hospital, Miami, Florida

⁸Harvard Community Health Plan, Boston, Massachusetts

⁹Shriners Hospital, Minneapolis, Minnesota

Ehlers-Danlos syndrome (EDS) type VII results from defects in the conversion of type I procollagen to collagen as a consequence of mutations in the substrate that alter the protease cleavage site (EDS type VIIA and VIIB) or in the protease itself (EDS type VIIC). We identified seven additional families in which EDS type VII is either dominantly inherited (one family with EDS type VIIB) or due to new dominant mutations (one family with EDS type VIIA and five families with EDS type VIIB). In six families, the mutations alter the consensus splice junctions, and, in the seventh family, the exon is deleted entirely. The *COL1A1* mutation produced the most severe phenotypic effects, whereas those in the *COL1A2* gene, regardless of the location or effect, produced congenital hip dislocation and other joint instability that was sometimes very

marked. Fractures are seen in some people with EDS type VII, consistent with alterations in mineral deposition on collagen fibrils in bony tissues. These new findings expand the array of mutations known to cause EDS type VII and provide insight into genotype/phenotype relationships in these genes. *Am. J. Med. Genet.* 72:94–105, 1997.

© 1997 Wiley-Liss, Inc.

KEY WORDS: Ehlers-Danlos syndrome; Ehlers-Danlos syndrome type VII; collagen; procollagen; exon skipping; exon deletion; alternative splicing; congenital hip dislocation

INTRODUCTION

The Ehlers-Danlos syndrome (EDS) is a group of inherited connective tissue disorders characterized by joint hypermobility, increased skin extensibility, bruising, abnormal scar formation, and, in some forms, aneurysm formation and propensity to bowel and uterine rupture [Beighton, 1970; McKusick, 1972; Beighton, 1993; Steinmann et al., 1993; Byers, 1995]. EDS type VII is distinguished from other types of EDS by the frequency of congenital hip dislocation and extreme joint laxity but minimal skin involvement [Lichtenstein et al., 1973; Steinmann et al., 1993].

EDS type VII is heterogeneous in terms of its molecular basis. EDS type VIIA results from mutations in

Grant sponsor: National Institutes of Health; Grant numbers: AR 21557, AR 03564.

Dr. Robinow is presently at 2638 Sutton Road, Yellow Springs, OH 45387.

Dr. Grealley is presently at the Arabian Gulf University, P.O. Box 26671, Manama, Bahrain, Arabian Gulf.

Dr. Matalon is presently at the Department of Pediatric Genetics, Children's Hospital, C-59, 301 University Boulevard, Galveston, TX 77555-3466.

*Correspondence to: Peter H. Byers, MD, University of Washington, Department of Pathology, Box 357470, Seattle, WA 98195-7470. E-mail: pbyers@u.washington.edu

Received 5 February 1997; Accepted 19 May 1997

the *COL1A1* gene that encodes the pro α 1(I) chains of type I procollagen [Weil et al., 1989; D'Alessio et al., 1991]. These mutations interfere with the normal splicing of exon 6, which encodes 24 amino acids that include the protease cleavage site at the amino-terminal end of the triple helix of the chain. Similar mutations in the *COL1A2* gene that encodes the pro α 2(I) chains of type I procollagen result in the EDS type VIIB phenotype [Weil et al 1988, 1989b, 1990; Nicholls et al., 1991; Vasan et al., 1991; Chiodo et al., 1992; Watson et al., 1992; Lehman et al., 1994; Ho et al., 1994]. Mutations that abolish the enzymatic activity of the N-proteinase itself result in a more severe phenotype, now termed EDS type VIIC in humans [Smith et al., 1992; Nusgens et al., 1992; Wertelecki et al., 1992; Petty et al., 1993; Reardon et al., 1995] and dermatosparaxis in animals [O'Hara et al., 1970; Lenaers et al., 1971].

Here, we describe individuals in seven additional families with mutations in the *COL1A1* gene or the *COL1A2* gene that have mutations in the splice donor or acceptor sites of exon 6 or delete the exon in *COL1A2* entirely. These mutations result in different splicing products from the two genes, result in disparate phenotypes, alter collagen fibril structure to different extents, and predispose to bone fracture.

MATERIALS AND METHODS

Clinical Description and Natural History

Family A. The index case, a female infant (Fig. 1, IV3), was born at term after an uncomplicated pregnancy and delivery to a healthy mother. At the age of 9 months, she was referred for evaluation because of joint laxity and inability to sit unsupported. Her feet and wrists could be dorsiflexed 180°, and her skin was soft and hyperextensible. Radiographs showed bilateral hip dislocations. Because bracing was unsuccessful in stabilizing her hips, at 16 months, she underwent open reduction of both hips, capsular reefing, and varus osteotomies with casting and bracing; these were not successful in preventing further dislocations. At the age of 32 months, open reduction of the right hip

with femoral osteotomy and a Salter osteotomy of the right ilium were performed. Following surgery, she walked with excessive eversion and subluxation of the talonavicular joints but without discomfort. Since then, she has sustained at least two hip dislocations from minor falls but has been able to reduce them herself. At the age of 6 years, she had normal intelligence. The child's father (Fig. 1, III-5) had bilateral hip dislocation identified at the age of 1 month. He underwent closed reduction, casting, and bracing without success. Subluxation of the metacarpophalangeal joint of one thumb, dislocation of the other, and subluxation of the first metatarsal joints were noted. At the ages of 11 and 14 years, he had dislocation of the right radial head, which he reduced. At the age of 17 years, he was 168 cm tall (tenth centile) and had chronically dislocated hips. He declined to donate blood samples for study. The index case's paternal uncle (Fig. 1, III-2) had bilateral congenital hip dislocation with unsuccessful correction; he was of average height. Two paternal aunts (III-3 and III-4) have not been examined but were reported to be unaffected.

IV-1, a first cousin of the index case, was noted at the age of 7 weeks to have dislocated hips and dislocations of the right elbow, patellas, fingers, and toes. Closed reduction of the hips was not successful, and his parents elected not to have surgery. His mother (III-1) and his sister (IV-2) are unaffected.

Radiographs of the index case's paternal grandfather (II-3) showed that he had bilateral hip dislocations; he walks with difficulty, using crutches. Both his parents were alive and unaffected. No affected relatives had fractures, dental or hearing abnormalities, blue sclerae, poor wound healing, or hernias described or reported.

Family B. The index case was 39 years old when he was evaluated. He was the product of a 38-week gestation and breech vaginal delivery. At birth, a severely clubbed left foot was noted; one thumb, his right and left radial heads, and both hips were dislocated. At birth, he had kyphosis and hypermobility of all joints; both femoral heads were absent by radiological examination. Multiple surgical attempts to reduce his bilateral hip dislocation were unsuccessful, as were attempts to repair clubbed feet and other dislocations. He never walked without support and generally did not use Canadian crutches extensively because of elbow and shoulder instability. He had bled excessively at surgery in the past, but results of hematologic evaluation were normal. Bladder diverticulae had developed previously and interfered sufficiently with function so that he relied on self-catheterization to void. At the age of 39 years, he had soft and lax skin without bruising. His forehead was prominent, and he had a depressed nasal bridge. He had extreme hypermobility of small and large joints, scoliosis and kyphosis, and severe equinovarus of both feet. His teeth were normal.

Family C. The index case was the only child of a normal nonconsanguineous couple, and there was no family history of connective tissue disorders. At birth, she was noted to be hypotonic with extensible skin and hypermobile large and small joints, and she had bilateral congenital hip dislocation. She had a leptomenin-

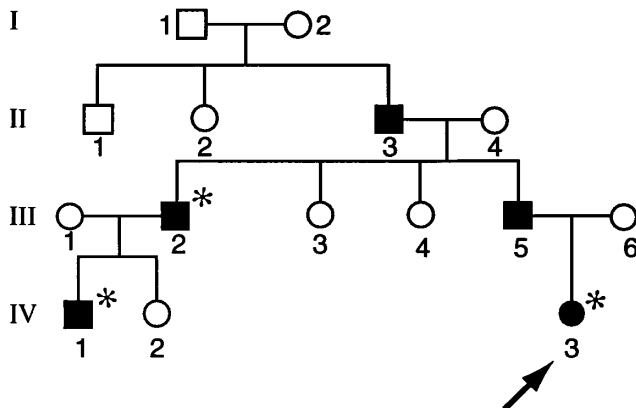


Fig. 1. Pedigree of family A. Inheritance of the phenotype in this family is consistent with an autosomal dominant disorder. Affected individuals are marked by black symbols, and the presence of the mutation was confirmed in those marked by an asterisk.

gocele in the right occipital region and had a right intracranial hemorrhage in the perinatal period. Her hips were treated with a Pavlik harness but without success. An open reduction was performed at the age of 2 months on both hips. Because of difficulty walking, a second bilateral open reduction with femoral osteotomies was performed at the age of 3 years. Further operations occurred at the age of 7 years. The meningocele was repaired after birth. She was left with mild cortical atrophy, a seizure disorder, palsy of the third cranial nerve, left hemiparesis, and a left homonymous hemianopsia. At the age of 10 years (the age of the skin biopsy), she walked with braces and had a normal range of cognitive function, but she was mildly delayed in school and had mild difficulties with articulation.

Family D. The index case was the first child born to 20-year-old normal, nonconsanguineous parents. He was noted to have joint laxity and bilateral hip dislocation at birth, which were treated with pelvic harness traction, spica case, and abduction brace. By the age of 17–18 months, he was able to ambulate independently. At the age of 20 months, he underwent open reduction of both hips with Pemberton pelvic osteotomies and varus derotation of the femoral osteotomies. He did not have joint dislocations other than the hips, although generalized joint hypermobility and ligamentous laxity were evident. At the age of 3.5 years, he fell onto his left hip and fractured his left femur. The fracture was treated by closed reduction and application of a spica cast. By the age of 7 years, there had been good healing of the fracture and osteotomy sites, with mild left coxa valga. In the cervical spine, 5 mm of anterior subluxation of C1 on C2 was noted, which was reduced to 4 mm with extension.

Family E. The fifth index case was adopted from Korea at the age of 9 months and arrived with hip spica casts because of bilateral hip dislocation. She was treated with braces until the age of 3 years, when bilateral surgical repair of both hips was performed successfully. At the age of 4 years, she had hypermobility of all large and small joints, soft skin without marked scarring, and had had no fractures.

Family F. The sixth index case was a 25-year-old woman who had carried a diagnosis of EDS since infancy because of bilateral congenital hip dislocation and marked joint laxity. Her hips required intermittent casting for a period of 5 years, but they were not treated surgically. She was the second of three children in the family and the only affected individual. Her nonconsanguineous parents had been 26 and 24 years old at the time of her birth; there was no family history of EDS or joint dislocation. During childhood, she had multiple dislocations of her shoulders, knees, and elbows. Following a fall at the age of 8 years, she sustained a fracture of her right radial head, and she fractured several ribs in a fall down stairs in her early 20s. She bruised easily. There was no history of ocular or cardiac difficulties, and an echocardiogram done at the age of 25 years was normal. On physical examination at the age of 25 years, she had marked hypermobility of large and small joints, with the exception of restricted motion at the right elbow. She had lordosis of the lower spine, with spondylolisthesis at L5-S1 on x-ray films,

and she had a mild thoracic scoliosis. Her skin was thin, soft, and hyperextensible. She had many scars. She was of normal height and had normal intelligence.

Family G. The seventh index case was the term product of a cesarean delivery for breech presentation and was born to a 23-year-old caucasian father and a 31-year-old mother of Japanese origin. At birth, she was noted to have large fontanelles, a small umbilical hernia, joint laxity, contractures of the second, third, and fourth digits of both hands, short femurs, and pendulous skin folds. Radiographs demonstrated bilateral hip dislocation. At the age of 5 months, she was at the 50th centile in length, had a head circumference at the 75th centile, and had patent and bulging fontanelles with prominent frontal bossing. She had a small chin, deep blue sclerae, a narrow thorax with a mild pectus excavatum, and a large umbilical hernia. Her large joints were hypermobile.

Biochemical Studies

Skin biopsies taken with consent from all individuals studied were explanted, and proteins were labeled and studied, as previously described [Bonadio et al., 1985], in the presence or absence of dextran sulfate [Bateman and Golub, 1990].

Electron Microscopy

Skin biopsies were fixed in half-strength Karnovsky's fixative, postfixed in 1% OsO₄, en bloc stained in 1% uranyl acetate, dehydrated, and embedded in Epon, as previously described [Holbrook and Byers, 1981]. Thin sections were collected onto copper grids; stained sequentially with phosphotungstic acid, uranyl acetate, and lead citrate; and then viewed by using a Philips 420 STEM transmission electron microscope.

Analysis of mRNA Transcripts

RNA was extracted from cultured fibroblasts with guanidine-isothiocyanate [Chomczynski and Sacchi, 1987], and cDNA was synthesized by using random hexamers [Fineberg and Vogelstein, 1984]. Sequences in the *COL1A1* and *COL1A2* cDNAs surrounding exon 6 were amplified [Saiki et al., 1988] by using sense primers in exon 5 (*COL1A1*) and exon 1 (*COL1A2*) and primers complementary to sequences in exon 8 (*COL1A1*) and exon 10 (*COL1A2*; Table I). The conditions for *COL1A1* were 94°C for 1.5 min, 65°C for 2 min, and 72°C for 2 min for 35 cycles; the conditions for *COL1A2* were 94°C for 1.5 min, 55°C for 2 min, and 72°C for 1 min for 35 cycles. The products were analyzed by electrophoresis on polyacrylamide gels and were stained with ethidium bromide.

The amplified products were separated by electrophoresis in low-melting-temperature agarose and then sequenced directly, or they were cloned in the TA cloning system (Invitrogen, San Diego, CA). Several normal and mutant clones from each population were selected and sequenced by using the di-deoxy chain-termination technique [Sanger et al., 1977] with amplification primers and Sequenase® (Amersham, Arlington Heights, IL).

Identification of Mutations in Genomic DNA

The DNA sequences surrounding exon 6 in the *COL1A1* or *COL1A2* gene were amplified by using published primer sequences for introns 5 and 6 in the *COL1A2* gene [Chiodo et al., 1992] and sequences in intron 5 and 6 of the *COL1A1* gene [D'Alessio et al., 1988]. The amplified fragments were purified by electrophoresis in low-melting-temperature agarose, and the purified fragments (containing both alleles) were sequenced directly, as described above, or the fragments were cloned in the TA system, and individual clones were sequenced.

RESULTS

Defective Conversion of Procollagen to Collagen in Three Cell Strains

The amounts of type I and type III procollagen synthesized by cells from the index case in each family were indistinguishable from controls. The apparent conversion of type I procollagen to collagen in the medium was unhindered in the cell strains (Fig. 2A,C). Following digestion with pepsin, there was an additional band that migrated between the $\alpha 1(I)$ and the $\alpha 2(I)$ chains of type I collagen in six cell strains (those from families A–F; Fig. 2B), and a faint additional band that migrated more slowly than the $\alpha 1(I)$ chains was apparent in the seventh cell strain (family G; Fig. 2D). Peptide maps of the abnormal band synthesized by cells from members of family A confirmed that it was related to the $\alpha 2(I)$ chain and appeared to contain an amino-terminal extension (data not shown). To determine whether the abnormal chains represented amino-terminal extensions of the pro $\alpha 2(I)$ and pro $\alpha 1(I)$ chains, we incubated cells with [³H]proline in the presence of dextran sulfate to promote conversion of procollagen to collagen. Six cell strains accumulated a chain in the cell layer that migrated between $\alpha 1(I)$ and $\alpha 2(I)$ chains (families A–F; Fig. 2A), whereas the seventh (family G) accumulated a chain that comigrated with pN $\alpha 1(I)$ chains (Fig. 2C). These findings suggested that, in the affected individuals from families A–F, mutations affected the cleavage of the amino-terminal propeptide of the pro $\alpha 2(I)$ chains, whereas in family G, the mutation affected the pro $\alpha 1(I)$ chains.

Identification of Mutations That Interfere With Amino-Terminal Processing

To identify the mutations in these seven cell strains, we reverse transcribed RNA. Then, by using the polymerase chain reaction, we amplified the regions surrounding exon 6 of either the *COL1A2* or the *COL1A1* cDNA. In cells from the index case in family A, amplification around exon 6 in the pro $\alpha 2(I)$ cDNA produced two bands, one of normal size and a second that was 15–20 bp smaller; the two bands were present in approximately equal amounts (Fig. 3). The DNA sequence of the two fragments showed the normal sequence in the band of normal size but demonstrated the loss of 15 bp from the shorter band (Fig. 4). The inferred peptide sequence of the smaller product was lacking the first five amino acids encoded by exon 6, Asn-Phe-Ala-Ala-Gln, which contain the N-proteinase site (Ala-Gln) and the pepsin-sensitive site (Phe-Ala; Fig. 5). At the genomic level, this cell strain contained a point mutation in the splice acceptor site (AG→GG; Fig. 5), which allowed the use of the cryptic 3'-splice site (AG) at position 14,15 of the exon (Fig. 6). The mutation in this family resulted in loss of an *Xba*I site (tctagA at the intron-exon border). To determine whether all members of the family carried the same allele (and to confirm the presence of the mutation in the index case), we amplified a short fragment surrounding the *COL1A2* exon 6 and digested the products with *Xba*I. In the DNA from the index case (Fig. 1, IV-3), her cousin (IV-1), and his father (III-2), three bands were apparent, the uncut amplified fragment and the digested fragments, consistent with the presence of one normal and one mutant allele; in the unaffected members of the family, only the digested products were apparent (data not shown).

In the cell strain from family B, amplification around exon 6 of the pro $\alpha 2(I)$ cDNA produced three bands, one that was in the normal position, one that was consistent with a small deletion, and a third that was consistent with the deletion of the entire exon 6 sequence (Fig. 3). The two shortened fragments corresponded to a deletion of 15 bp, identical to that seen in cells from family A, and deletion of the entire sequence of exon 6. At the genomic level, this cell strain contained a point mutation in the splice acceptor site (AG→AA; Fig. 5)

TABLE I. Primers Used for cDNA and Genomic Amplification

Location	Sequence
<i>COL1A1</i> ^a	
Intron 5 (sense)	5' CAAGAGCATTCTCTTAACCTGACCT 3'
Intron 6 (antisense)	5' CATGGTGATCCCTCTGTAGGA 3'
Exon 5 (sense)	5' AGATGGCATCCCTGGACAGCCTGGACTTC 3'
Exon 8 (antisense)	5' CAGGCTCACCAGGGGACCTTGAAGC 3'
<i>COL1A2</i> ^b	
Intron 5 (sense)	5' GTGGGAGTGGAGACACCGAGTT 3'
Intron 6 (antisense)	5' CTAAGTATTGAGTGTTAACTT 3'
Exon 1 (sense)	5' CAGGGCTCTGCGACACAAGGAGTCGCATG 3'
Exon 10 (antisense)	5' TCCAACAACCTCTCTCACCA 3'

^aThe genomic primers amplify a product of 732 bp; the cDNA primers amplify a product of 233 bp.

^bThe genomic primers amplify a product of 453 bp; the cDNA primers amplify a product of 523 bp.

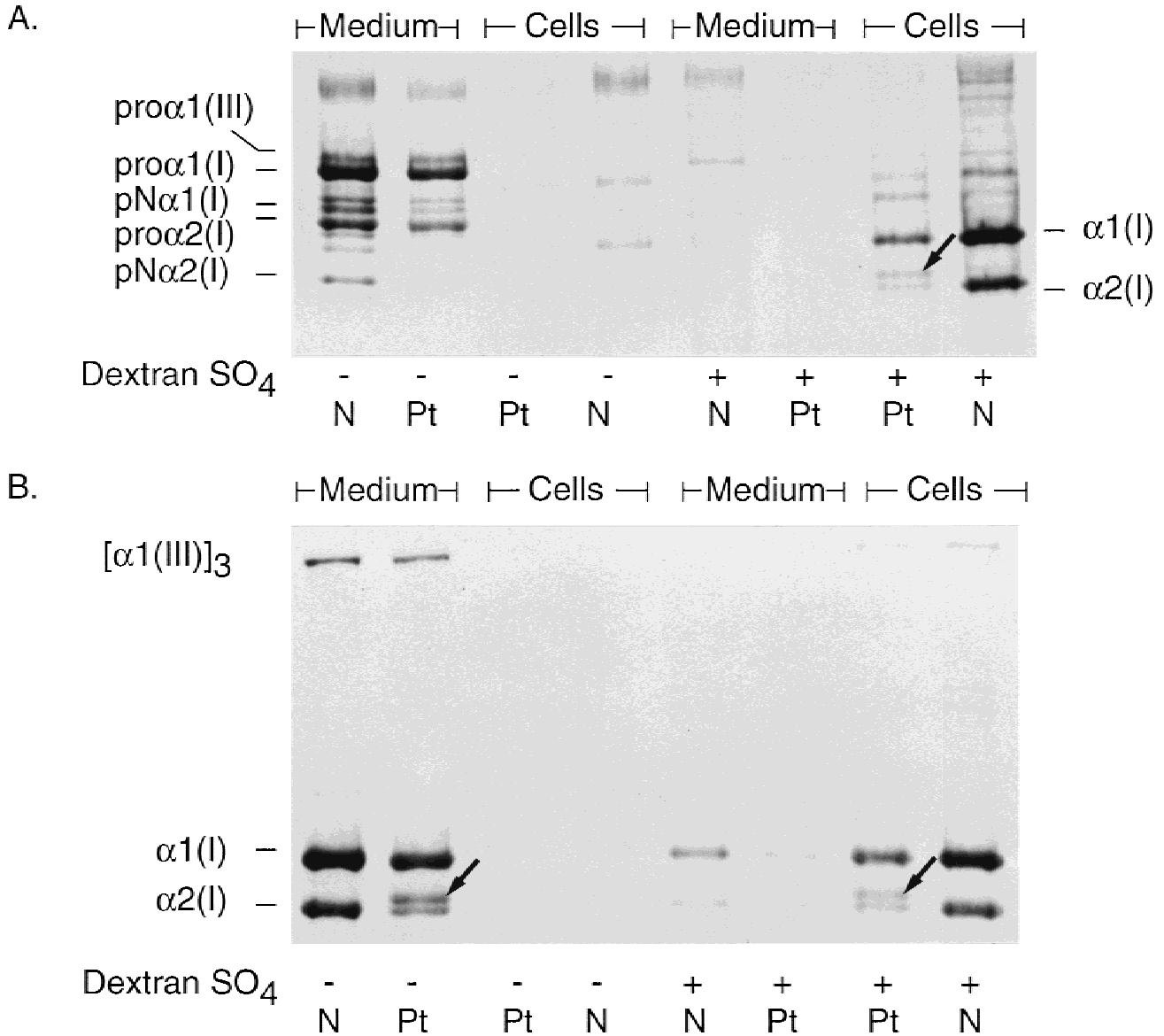


Fig. 2.

that permitted both the complete excision of the exon and the use of the internal cryptic splice site at position 14,15 of the exon (Fig. 6). The mutation disrupted an *Xba*I site; digestion of the amplified genomic DNA product with *Xba*I confirmed that the DNA from the affected individual contained one normal and one mutant allele (data not shown).

In the cell strains from families C, D, E, and F, amplification around exon 6 of the pro α 2(I) cDNA demonstrated two bands, the normal fragment and one approximately 50 bp smaller, in about equal amounts (Fig. 3). In each instance, the small fragment lacked the entire sequence of exon 6, thus deleting 18 amino acids that included the pepsin-sensitive site, the N-proteinase site, and a lysyl residue used in cross-link formation (Fig. 5). At the genomic level, cell strains C and D contained a point mutation in the splice donor site (GT→TT) of one *COL1A2* allele (Fig. 5), which re-

sulted in complete skipping of exon 6 (Fig. 6). In cell strain E, there was substitution of the last nucleotide (G) of exon 6 by A (Fig. 5). In cell strain F, there was an 83-bp deletion from one *COL1A2* allele that included 17 bp of intron 5, the 54 bp of exon 6, and 12 bp of intron 6 (Fig. 5). In cell strains from index cases in families C, D, and F, the excision of exon 6 was the only consequence of the mutation. In cell strain E, there was alternative splicing, so that some products of the mutant allele included the exon, with the resultant amino acid substitution of isoleucine for methionine (Figs. 5, 6).

In the seventh cell strain (family G), amplification around exon 6 of the pro α 1(I) cDNA produced three bands, one of the normal size, one about 15–20 bp smaller, and the third equivalent to the product expected with deletion of the sequence of the entire exon (Fig. 3). The last two were in approximately equal

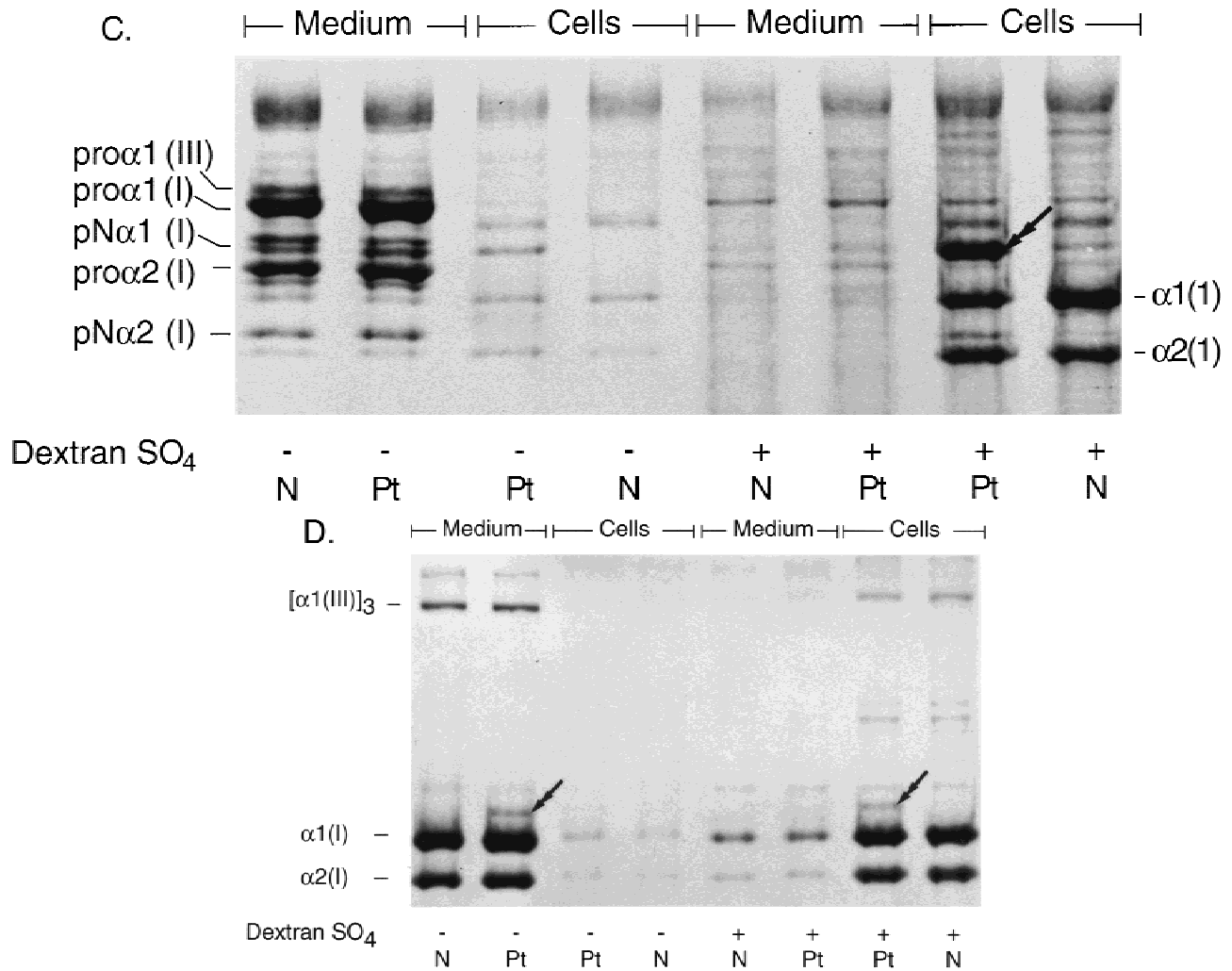


Fig. 2. Sodium dodecyl sulfate-polyacrylamide gel electrophoresis (SDS-PAGE) of procollagens synthesized in the presence or absence of dextran sulfate by cells from the index cases in family B (A,B) and family G (C and D). Cells were incubated with [³H]proline overnight in the presence or absence of dextran sulfate to enhance conversion of procollagen to collagen. Medium and cell layer samples were harvested separately and analyzed by SDS-PAGE under reducing conditions (A,C) or under nonreducing conditions following partial proteolysis with pepsin (B,D). In cells from the index case in family B, in the presence of dextran sulfate a band is present in the position of pNα2(I) (arrow), which is resistant to proteolytic cleavage. In the cells from the index case in family G, in the presence of dextran sulfate, a band is present in the position of pNα1(I) (C, double arrow) that is only partly resistant to proteolysis. In the presence of dextran sulfate, the majority of secreted procollagen is precipitated in the extracellular matrix of the cell layer and is converted to collagen by partial proteolysis.

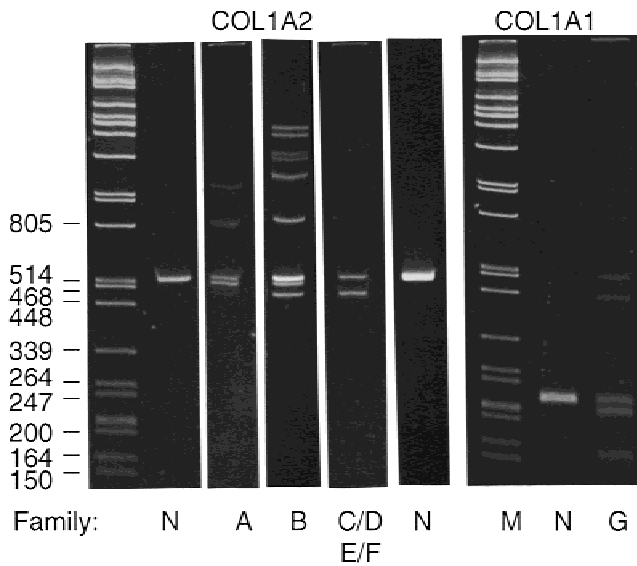


Fig. 3. Polymerase chain reaction amplification of cDNA from cultured fibroblasts from index cases of families A-F (*COL1A2*) and family G (*COL1A1*). For the *COL1A2* fragments, the normal band is 523 bp. The products from the index case in family A are the normal and are a product smaller by 15 bp. For the index case in family B, the three products are the normal fragment and two shortened fragments, one that is missing 15 bp and a second that is missing the entire exon. The amplification products from the index cases in families C, D, E, and F were identical; those shown are from family C. The amplification product from the *COL1A1* cDNA is 233 bp in size. The additional products amplified from the cDNA from the index case in family G represent one fragment missing 15 bp and a second missing the entire exon. The bands above the normal fragments represent heteroduplexes formed at the last rounds of amplification between the different products.

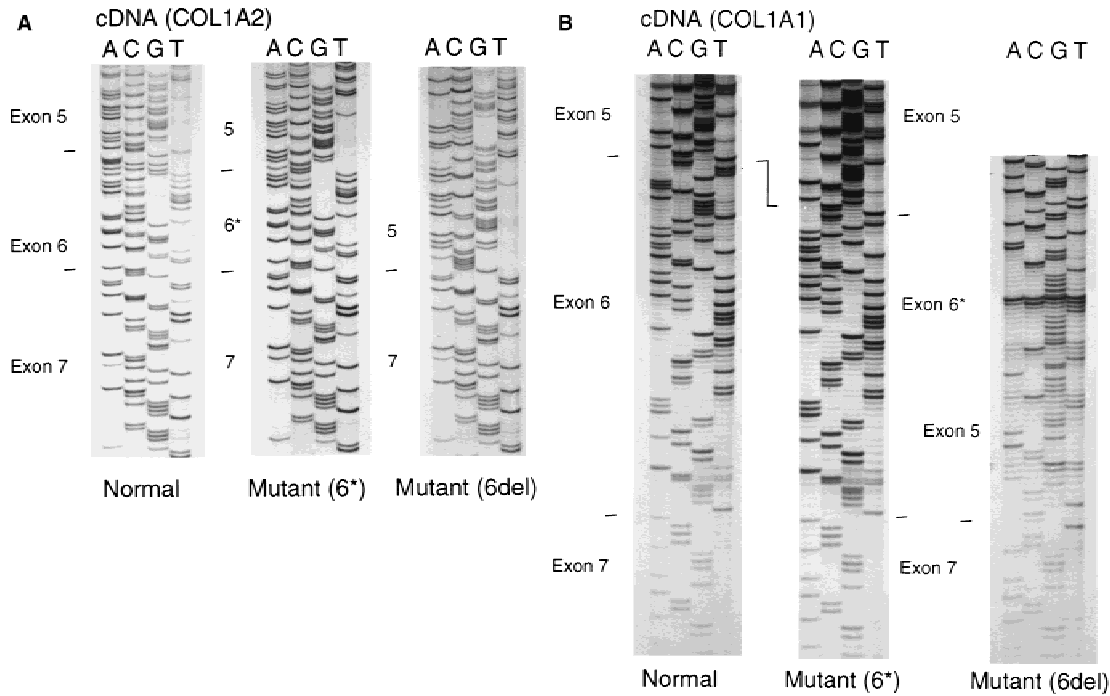



Fig. 4. DNA sequence of abnormal cDNAs from *COL1A2* (A) and from *COL1A1* (B). Three different transcripts were identified from *COL1A2* and three from *COL1A1* in the different families. The complete sequence of exon 6 was always present. A: The three products of the *COL1A2* alleles are the full-length fragment (normal), the fragment missing 15 nt (6*), and the fragment missing the entire sequence of exon 6 (6del). All three products were identified in the cells from the index case in family B (from which these sequences are derived). The cells from the patients in family A made the normal product and the 6* product, whereas those from the index cases in families C, D, E, and F made the normal product and the 6del product. B: The three products of the *COL1A1* alleles synthesized by the cells from the index case in family G are the full length transcript (normal), one missing 15 nt (6*) and one missing the sequence of exon 6 (6del). All sequences were determined from the complement of the message equivalent strand.

amounts (Fig. 3). The sequence of the smaller band indicated that there was a deletion of 15 bp (Fig. 4) encoding five amino acids (Asn-Phe-Ala-Pro-Gln), which include the pepsin-sensitive site (Phe-Ala) and the N-proteinase cleavage site (Pro-Gln; Fig. 5). At the genomic level in this cell strain, one allele has a G→A transition in the splice-acceptor site (AG→AA; Fig. 5).

The cryptic splice site at position 14,15 of the exon, as a consequence of the mutation, is activated but is used only part of the time. (Fig. 6). The mutation disrupts an *Xba*I site; digestion with *Xba*I of amplified DNA surrounding *COL1A1* exon 6 from the index case confirmed the presence of the mutant sequence in one allele (data not shown).

COL1A2



COL1A1

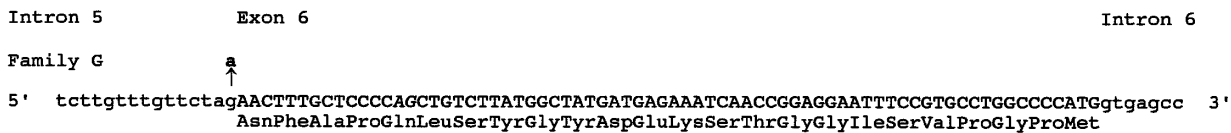


Fig. 5. Representation of sequence and mutations in genomic DNA. The complete sequences of exons 6 (upper case letters) in the *COL1A1* and *COL1A2* genes and the sites of mutation in each family are indicated. The extent of the genomic deletion of one *COL1A2* allele in family F is underlined. The AG dinucleotides at position 14,15 of both the *COL1A2* and *COL1A1* gene are italicized and represent the cryptic splice-acceptor sites. The T/C polymorphism in the third position of the Asp codon of the *COL1A2* exon is indicated.

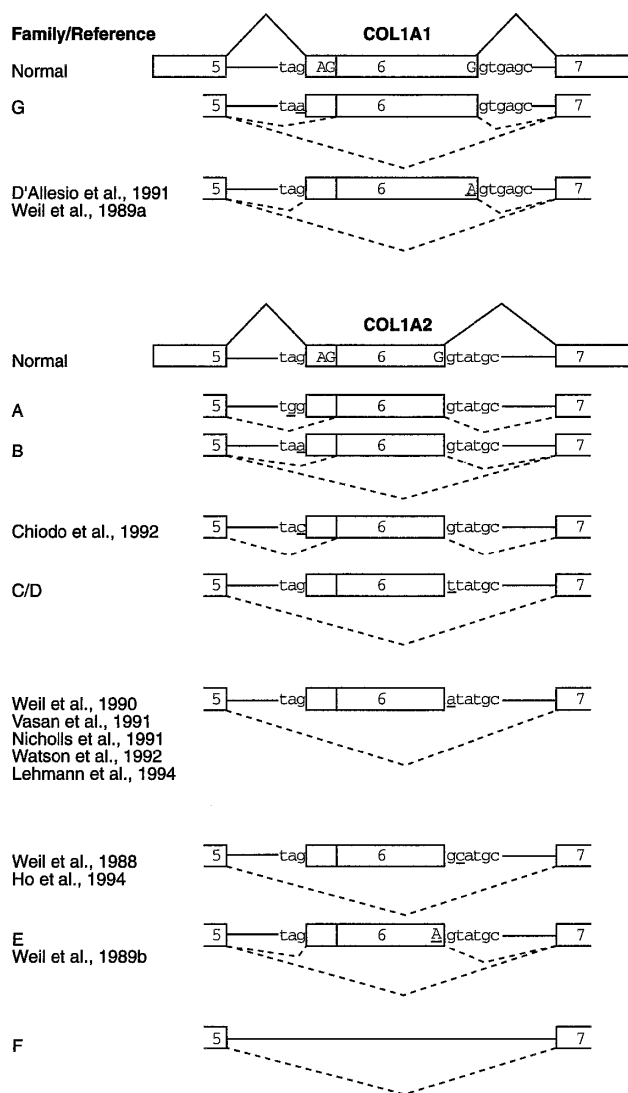


Fig. 6. Effects of different mutations on *COL1A2* and *COL1A1* mRNA processing. Exons are represented by boxes, and intron sequences are represented by the straight lines that join the boxes, including the nucleotides of the 3' and 5' splice sites. The AG within the exon of both of the normal *COL1A1* and *COL1A2* genes are at position 14,15 of the exon and represent the cryptic 3' splice sites. The normal splicing pathway is indicated by the lines that join the adjacent exons in the normal schematic. The new splice pathways with each mutation are indicated by the dashed lines.

Effect of the Mutations on Fibril Formation in Skin

Fibrils in skin from the index case and her cousin in family A were somewhat irregular, and the interfibrillar spacing was less uniform than in the control (Fig. 7). Fibrils in skin from the index case in family G were far more irregular than either the control or those from family A (Fig. 7). They were not as distorted as fibrils from individuals with EDS type VIIC, a defect in the type I procollagen N-proteinase that abolishes proteolytic conversion at the amino-terminal end.

A sample of the dermis from the index case in family D was digested with 50 $\mu\text{g}/\text{ml}$ of pepsin in 0.5 M acetic acid at 2°C for 48 hours, and the chains of type I collagen were resolved by sodium dodecyl sulfate-

polyacrylamide gel electrophoresis (SDS-PAGE) and were stained with Coomassie blue. There was a minor band that migrated more slowly than the $\alpha 2(\text{I})$ chains, consistent with the position of the abnormal band observed in collagen labeled from his cells in culture. This more slowly migrating band was not observed in samples from normal subjects. Thus, the partially processed $\alpha 2(\text{I})$ chain is present in heterotrimers deposited in skin and explains, in part, the altered fibril structure.

DISCUSSION

EDS type VII was first described more than 20 years ago [Lichtenstein et al., 1973], when, in the context of the then recent discoveries of procollagen N-proteinase deficiency in cattle [Lenaers et al., 1971], it was thought to be the consequence of failure of enzymatic cleavage of the amino-terminal propeptide from type I procollagen molecules. Studies by Steinmann et al. [1980] first raised the possibility that the defective cleavage of the type I procollagen molecules could be the result of a mutation in one of the genes (*COL1A1* and *COL1A2*) that encode the substrate chains [$\text{pro}\alpha 1(\text{I})$ or $\text{pro}\alpha 2(\text{I})$], an idea that proved to be correct.

The seven affected individuals described here bring the total in the literature to 16, all but one of whom have mutations in the splice-junction sequences of the *COL1A1* gene (three individuals) or the *COL1A2* gene (12 individuals). These previously reported mutations affect the splice donor site of the *COL1A2* gene [Weil et al., 1988, 1990; Nicholls et al., 1991; Vasan et al., 1991; Watson et al., 1992; Ho et al., 1994; Lehman et al., 1994], the last nucleotide of the exon in the *COL1A2* gene [Weil et al., 1989b], the splice-acceptor site of the *COL1A2* gene [Chiodo et al., 1992], or the last nucleotide of exon 6 in the *COL1A1* gene [Weil et al., 1989a; D'Allesio et al., 1991].

The splice-acceptor site mutations result in efficient recognition of a cryptic splice site in exon 6 of each gene. In both genes, when the G^{-1} nucleotide is substituted by A in intron 5, there is alternative splicing from the same allele, so that the internal cryptic site is used about half of the time, and exon 6 is skipped in the remainder. The $\text{G}\rightarrow\text{A}$ transition creates a sequence that is more similar to the consensus branch-point sequence than the ones normally employed (for a model, see Fig. 8). The coexistence of this putative alternative branch site and the constitutive branch-point sequence may lead to competition for interaction with U2 snRNP, a branch site binding molecule. The new branch point A (the second A of the CUA sequence derived from the normal CUAG sequence at the original splice acceptor site) is too close to the cryptic acceptor site to prevent steric hindrance between splicing factors that are essential for splice-site recognition. Consequently, pairing of the cryptic acceptor and the downstream donor site probably would be inhibited and would lead to exon 6 skipping due to lack of exon definition [Berget, 1995]. Substitution at the intron 5 G^{-1} position by C or at the A^{-2} position by G supports the recognition of the cryptic internal splice-acceptor site (see Fig. 6) in all transcripts. In these instances, there would not be com-

TABLE II. Clinical Findings in Individuals With Ehlers-Danlos Syndrome Type VII

Family or reference	CHD ^a	Dislocation	Scoliosis	Fractures	Bruising	Scars	Family history	Gene	Mutation
Family A	+	+		-			+	COL1A2	Intron 5 A ⁻² →G
Family B	+	+	+	-			-	COL1A2	Intron 5 G ⁻¹ →A
Chiodo et al., 1992	+	+	+	+	+	+	+	COL1A2	Intron 5 G ⁻¹ →C
Family E	+			-			NA ^b	COL1A2	Exon 6 G ⁻¹ →A
Weil et al., 1989b ^c	+	+					-	COL1A2	Exon 6 G ⁻¹ →A
Vasan et al., 1991	+	+	+		+		-	COL1A2	Intron 6 G ⁺¹ →A
Nicholls et al., 1991	+	+	+				+	COL1A2	Intron 6 G ⁺¹ →A
Weil et al., 1990 ^d	+	+					-	COL1A2	Intron 6 G ⁺¹ →A
Lehmann et al., 1994	+					+	-	COL1A2	Intron 6 G ⁺¹ →A
Watson et al., 1992 ^e	+	+		+			+	COL1A2	Intron 6 G ⁺¹ →A
Family C	+						-	COL1A2	Intron 6 G ⁺¹ →T
Family D	+	+		+			-	COL1A2	Intron 6 G ⁺¹ →T
Weil et al., 1988 ^f	+	+					-	COL1A2	Intron 6 T ⁺² →C
Ho et al., 1994	+	+			+		-	COL1A2	Intron 6 T ⁺² →C
Family F	+	+	+	+	+	+	-	COL1A2	Exon 6 deletion
Family G	+						-	COL1A1	Intron 5 G ⁻¹ →A
D'Allesio et al., 1991	+	+	+	+			-	COL1A1	Exon 6 G ⁻¹ →A
Weil et al., 1989a ^g	+	+	+				-	COL1A1	Exon 6 G ⁻¹ →A

^aCHD, congenital hip dislocation.

^bNA, not available.

^cClinical information is also contained in Steinmann et al. [1980] and Lichtenstein et al. [1973].

^dClinical information is also contained in Eyre et al. [1985].

^eClinical information is also contained in Viljoen et al. [1987].

^fClinical information is also contained in Wirtz et al. [1987, 1990] and Steinmann et al. [1985].

^gClinical information is also contained in Cole et al. [1987].

cleaves the amino-terminal propeptide within all three chains [Hojima et al., 1994]. Cleavage by the enzyme is thought to require that the procollagen molecule is in triple helical array and that all three chains are in register [Tanzawa et al., 1985]. In the presence of dextran sulfate, normal cells convert virtually all of the procollagen in the extracellular matrix of the cell layer to collagen. Cells with *COL1A2* mutations fail to cleave about half of the pro α 2(I) chains but successfully cleave far more than half of the pro α 1(I) chains. Each abnormal molecule would contain one abnormal pro α 2(I) chain and two normal pro α 1(I) chains (see Fig. 2). If cleavage is dependent upon normal conformation and sequence of all three chains in the molecule, then it would be expected that the accumulation of noncleaved pro α 1(I) chains would approximate that of pro α 2(I) chains. There is less radioactivity in the pN α 1(I) chains than in the pN α 2(I) chains, suggesting that many of the pro α 1(I) chains in the abnormal molecules can be converted. In a similar but more dramatic fashion, cells from the child in family G (splice-acceptor mutation in the *COL1A1* gene that activates an internal splice site in exon 6) cleave the amino-terminal propeptide of the pro α 2(I) chains less efficiently than the normal cells but fail to cleave about half of the pro α 1(I) chains. These findings suggest that no chains in molecules that contain two abnormal pro α 1(I) chains can be cleaved but that pro α 2(I) chains in those molecules that contain only a single abnormal pro α 1(I) chain (or only normal chains) can be cleaved normally. Thus, some chains in the abnormal molecules can be cleaved efficiently.

The clinical effects of mutations that alter amino-terminal propeptide cleavage vary, depending on the gene in which the mutation occurs and the effect of the mutation on excision of the propeptide. The most se-

vere phenotype results from mutations that affect the enzyme procollagen N-proteinase, which cleaves the amino-terminal propeptide. These children have striking joint hypermobility, soft and fragile skin, easy bruising, a small chin, blue sclerae, mild hirsutism, and wrinkled skin over the hands and feet [Nusgens et al., 1992; Smith et al., 1992; Wertelecki et al., 1992; Petty et al., 1993; Reardon et al., 1995].

Out of all those reported with splice-junction mutations (for summary, see Table II), the phenotype of the patient in family G (who has a *COL1A1* mutation) bears the greatest similarity to the children with EDS type VIIC. This affected child has very marked joint laxity, deep blue sclerae, and a large umbilical hernia. The other two children described, who have mutations in the *COL1A1* gene, both have substitutions for the last nucleotide of exon 6. This results in alternative splicing, so that part of the product deletes the exon sequence from mRNA, whereas the remainder permits normal splicing, and the protein product contains an isoleucine at position 3 of the triple helix in place of methionine. In those instances, the proportion of the protein product that cannot be cleaved is far smaller, and the effect on fibrillogenesis in skin is less dramatic (compare with Fig. 8 in Carr et al. [1994]). It is not clear that the clinical phenotypes of the different mutations in the *COL1A2* gene can be distinguished in a reliable fashion. For mutations in the substrate, those in the *COL1A1* gene do appear to give rise to a more severe phenotypic expression than those in the *COL1A2* gene. This would be expected, because there are two pro α 1(I) chains in each type I procollagen and only a single pro α 2(I) chain. Thus, heterozygosity for mutations in the *COL1A1* gene would be expected to affect three-fourths of the type I procollagen molecules

synthesized, whereas those in the *COL1A2* gene would affect only half.

Although these mutations result in phenotypes that are expressed principally in soft tissues (skin and ligaments), bone fragility is an element in some individuals (see Table I). Indeed, one family was initially thought to have a variant of osteogenesis imperfecta with multiple fractures, blue sclerae, and wormian bones [Viljoen et al., 1987; Watson et al., 1992]. In mineralized tissues, initial deposits of the inorganic mineral phase occur in the hole zones of the collagen fibrils, regions that would be occupied by the amino-terminal propeptides if they were present. Thus, retention of the peptides might result in alterations in bone mineral density and strength, and, although they are not as dramatic as mutations within the triple helix, it is now apparent that fractures must be considered as part of the clinical features of EDS type VII.

ACKNOWLEDGMENTS

We thank the families for participating in these studies, Laura Suesserman for culturing the cells, Diana Chen for doing the protein analysis, Barbara Kovacich for assistance with the paper, and Kris Carroll for constructing the figures.

REFERENCES

- Bateman JF, Golub SB (1990): Assessment of procollagen processing defects by fibroblasts cultured in the presence of dextran sulfate. *Biochem J* 267:573-577.
- Beighton P (1970): "The Ehlers-Danlos Syndrome." London: William Heinemann Books, Ltd.
- Beighton P (1993): The Ehlers-Danlos syndrome. In Beighton P (ed): "McKusick's Heritable Disorders of Connective Tissue," 5th ed. St. Louis: Mosby, pp 189-254.
- Berget SM (1995): Exon recognition in vertebrate splicing. *J Biol Chem* 270:2411-2414.
- Bonadio JF, Holbrook KA, Gelinis RE, Jacob J, Byers PH (1985): Altered triple helical structure of type I procollagen in lethal perinatal osteogenesis imperfecta. *J Biol Chem* 260:1734-1742.
- Byers PH (1995): Disorders of collagen structure and synthesis. In Scriver CR, Beaudet A, Sly W, Valle D (eds): "The Metabolic and Molecular Bases of Inherited Disease," 7th ed. New York: McGraw-Hill, pp 4029-4078.
- Carr AJ, Chiodo AA, Hilton JMN, Chow CW, Hockey A, Cole WG (1994): The clinical features of Ehlers-Danlos syndrome type VIIB resulting from a base substitution at the splice acceptor site of intron 5 of the *COL1A2* gene. *J Med Genet* 31:306-311.
- Chiodo AA, Hockey A, Cole WG (1992): A base substitution at the splice acceptor site of intron 5 of the *COL1A2* gene activates a cryptic splice site within exon 6 and generates abnormal type I procollagen in a patient with Ehlers-Danlos syndrome type VII. *J Biol Chem* 267:6361-6369.
- Chomczynski P, Sacchi N (1987): Single step method for RNA isolation by acid guanidinium thiocyanate-phenol-chloroform extraction. *Anal Biochem* 162:156-159.
- Cole WG, Evans R, Silience DO (1987): The clinical features of Ehlers-Danlos syndrome type VII due to a deletion of 24 amino acids from the pro α 1(I) chain of type I procollagen. *J Med Genet* 24:698-701.
- D'Alessio M, Bernard M, Pretorius PJ, de Wet W, Ramirez F (1988): Complete nucleotide sequence of the region encompassing the first twenty-five exons of the human pro α 1(I) collagen gene (*COL1A1*). *Gene* 67:105-115.
- D'Alessio M, Ramirez F, Blumberg BD, Wirtz MK, Rao VH, Godfrey MD, Hollister DW (1991): Characterization of a *COL1A1* splicing defect in a case of Ehlers-Danlos syndrome type VII: Further evidence of molecular homogeneity. *Am J Hum Genet* 49:400-406.
- Eyre DR, Shapiro FD, Aldridge JF (1985): A heterozygous collagen defect in a variant of the Ehlers-Danlos syndrome type VII. *J Biol Chem* 266:11322-11329.
- Fineberg AP, Vogelstein B (1984): Addendum: A technique for radiolabeling DNA restriction endonuclease fragments to high specific activity. *Anal Biochem* 137:266-267.
- Ho KK, Kong RY, Kuffner T, Hsu LH, Ma L, Cheah KS (1994): Further evidence that the failure to cleave the aminopropeptide of type I procollagen is the cause of Ehlers-Danlos syndrome type VII. *Hum Mutat* 3:358-364.
- Hojima Y, Morgelin MM, Engel J, Boutillon MM, van der Rest M, McKenzie J, Chen GC, Rafi N, Romanic AM, Prockop DJ (1994): Characterization of type I procollagen N-proteinase from fetal bovine tendon and skin. Purification of the 500-kilodalton form of the enzyme from bovine tendon. *J Biol Chem* 269:11381-11390.
- Holbrook KA, Byers PH (1981): Ultrastructural characteristics of the skin in a form of the Ehlers-Danlos syndrome type IV: Storage in the rough endoplasmic reticulum. *Lab Invest* 44:342-350.
- Lehmann HW, Mundlos S, Winterpacht A, Brenner RE, Zabel B, Muller PK (1994): Ehlers-Danlos syndrome type VII: Phenotype and genotype. *Arch Dermatol Res* 286:425-428.
- Lenaers A, Ansay M, Nusgens BV, Lapière CM (1971): Collagen made of extended α -chains, procollagen, in genetically-defective dermatosparaxical calves. *Eur J Biochem* 23:533-543.
- Lichtenstein JR, Martin GR, Kohn LD, Byers PH, McKusick VA (1973): Defect in conversion of procollagen to collagen in a form of Ehlers-Danlos syndrome. *Science* 182:298-300.
- McKusick VA (1972): Ehlers-Danlos syndrome. In McKusick VA (ed): "Heritable Disorders of Connective Tissue," 4th ed. St. Louis: CV Mosby, pp 292-371.
- Nicholls AC, Oliver J, Renouf DV, McPheat J, Palan A, Pope FM (1991): Ehlers-Danlos syndrome type VII: A single base change that causes exon skipping in the type I collagen α 2(I) chain. *Hum Genet* 87:193-198.
- Nusgens BV, Verellen-Dumoulin C, Hermanns LT, De Paep A, Nuytinck L, Piérard GE, Lapière CM (1992): Evidence for a relationship between Ehlers-Danlos type VIIC in humans and bovine dermatosparaxis. *Nature Genet* 1:214-217.
- O'Hara PJ, Read WK, Romane WM, Bridges CH (1970): A collagenous tissue dysplasia of calves. *Lab Invest* 23:307-314.
- Petty EM, Seashore MR, Braverman IM, Spiesel SZ, Smith LT, Milstone LM (1993): Dermatosparaxis in children. A case report and review of the newly recognized phenotype. *Arch Dermatol* 129:1310-1315.
- Reardon W, Winter RM, Smith LT, Lake BD, Rossiter M, Baraitser M (1995): The natural history of human dermatosparaxis (Ehlers-Danlos syndrome type VIIC). *Clin Dysmorphol* 4:1-11.
- Saiki RK, Gelfand DH, Stoffel S, Scharf SJ, Higuchi R, Horn GT, Mullis KB, Erlich HA (1988): Primer-directed enzymatic amplification of DNA with a thermostable DNA polymerase. *Science* 239:487-491.
- Sanger F, Nicklen S, Coulson AR (1977): DNA sequencing with chain-terminating inhibitors. *Proc Natl Acad Sci USA* 74:5463-5467.
- Smith LT, Wertelecki W, Milstone LM, Petty EM, Seashore MR, Braverman IM, Jenkins TG, Byers PH (1992): Human dermatosparaxis: A form of Ehlers-Danlos syndrome that results from failure to remove the amino-terminal propeptide of type I procollagen. *Am J Hum Genet* 51:235-244.
- Steinmann B, Tuderman L, Peltonen L, Martin GR, McKusick VA, Prockop DJ (1980): Evidence for a structural mutation of procollagen type I in a patient with the Ehlers-Danlos syndrome type VII. *J Biol Chem* 255:8887-8893.
- Steinmann B, Rao VH, Gitzelmann R (1985): A structurally abnormal α 2(I) collagen chain in a further patient with Ehlers-Danlos syndrome type VII. *Ann NY Acad Sci* 460:506-509.
- Steinmann B, Royce PM, Superti-Furga A (1993): The Ehlers-Danlos syndrome. In Steinmann B, Royce PM (eds): "Connective Tissue and its Heritable Disorders. Molecular, Genetic and Medical Aspects." New York: Wiley-Liss, Inc., pp 351-408.
- Tanzawa K, Berget J, Prockop DJ (1985): Type I procollagen N-proteinase from whole chick embryos. Cleavage of a homotrimer of pro α 1(I) chains and the requirement for procollagen with a triple-helical conformation. *J Biol Chem* 260:1120-1126.
- Vasan NS, Kuivaniemi H, Vogel BE, Minor RR, Wootton JAM, Tromp G, Weksberg R, Prockop DJ (1991): A mutation in the pro α 2(I) gene (*COL1A2*) for type I procollagen in Ehlers-Danlos syndrome type VII: Evidence suggesting that skipping of exon 6 in RNA splicing may be a common cause of the phenotype. *Am J Hum Genet* 48:305-317.

- Viljoen D, Goldblatt J, Thompson D, Beighton P (1987): Ehlers-Danlos syndrome: yet another type? *Clin Genet* 32:196–201.
- Watson RB, Wallis GA, Holmes DR, Viljoen D, Byers PH, Kadler KE (1992): Ehlers-Danlos syndrome type VIIB. *J Biol Chem* 267:9093–9100.
- Weil D, Bernard M, Combates N, Wirtz MK, Hollister DW, Steinmann B, Ramirez F (1988): Identification of a mutation that causes exon skipping during collagen pre-mRNA splicing in an Ehlers-Danlos syndrome variant. *J Biol Chem* 263:8561–8564.
- Weil D, D'Alessio M, Ramirez F, de Wet W, Cole WG, Chan D, Bateman JF (1989a): A base substitution in the exon of a collagen gene causes alternative splicing and generates a structurally abnormal polypeptide in a patient with Ehlers-Danlos syndrome type VII. *EMBO J* 8:1705–1710.
- Weil D, D'Alessio MD, Ramirez F, Steinmann B, Wirtz MK, Glanville RW, Hollister DW (1989b): Temperature-dependent expression of a collagen splicing defect in the fibroblasts of a patient with Ehlers-Danlos syndrome type VII. *J Biol Chem* 264:16804–16809.
- Weil D, D'Alessio M, Ramirez F, Eyre DR (1990): Structural and functional characterization of a splicing mutation in the pro α 2(I) collagen genes of an Ehlers-Danlos type VII patient. *J Biol Chem* 265:16007–16011.
- Wertelecki W, Smith LT, Byers P (1992): Initial observations of human dermatosparaxis: Ehlers-Danlos syndrome type VIIC. *J Pediatr* 121:558–564.
- Wirtz MK, Glanville RW, Steinmann B, Rao VH, Hollister DW (1987): Ehlers-Danlos syndrome type VIIB: Deletion of 18 amino acids composing the N-telopeptide region of a pro α 2(I) chain. *J Biol Chem* 262:16376–16385.
- Wirtz MK, Keene DR, Hori H, Glanville RW, Steinmann B, Rao VH, Hollister DW (1990): *In vivo* and *in vitro* noncovalent association of excised α 1(I) amino-terminal propeptides with mutant pN α 2(I) collagen chains in native mutant collagen in a case of Ehlers-Danlos syndrome, type VII. *J Biol Chem* 265:6312–6317.